

# 3D Ultrasound-Guided Retrieval of Foreign Bodies from a Beating Heart using a Dexterous Surgical Robot

Paul Thienphrapa<sup>1,\*</sup>, Aleksandra Popovic<sup>2</sup>, Russell H. Taylor<sup>1</sup>

<sup>1</sup>ERC CISST/LCSR, Johns Hopkins University; <sup>2</sup>Philips Research North America

## INTRODUCTION

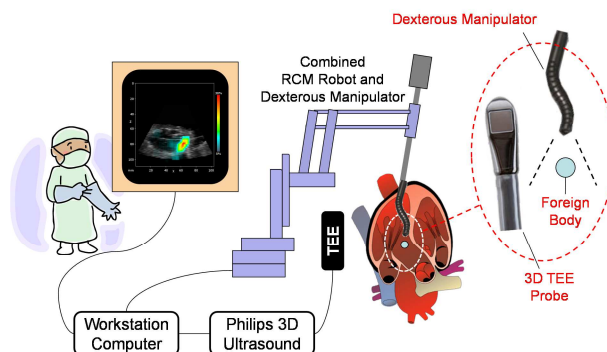
Foreign bodies in the heart (e.g. thrombi, shrapnel) can cause a series of adverse symptoms, such as arrhythmia, cardiac tamponade, hemorrhage, infection, embolism, valve dysfunction, and anxiety, and have to be removed surgically<sup>1,2</sup>. The most frequent surgical approach for removing foreign bodies from the heart is a median sternotomy followed by an incision in the heart muscle to gain direct access to the object<sup>3-6</sup>. Median sternotomy is a highly invasive procedure imposing risks such as bacterial mediastinitis, inflammation, bone fracture, and vulnerability to future chest injury. Cardiopulmonary bypass (CPB), which is often used to stop the heart during surgery, is associated with risks of hemolysis, clotting, and air embolism, and can lead to extended durations of procedures as well.

To address the disadvantages of the open surgery, we propose a minimally invasive, transapical approach for retrieving foreign bodies from a beating heart. The task is carried out using a dexterous robotic capture device, with 3D transesophageal echocardiography (TEE) providing internal visualization of the otherwise occluded heart chamber, foreign body, and robot. Under intraoperative ultrasound guidance, the robot moves to secure the target; the setup is illustrated in Fig. 1. This proposed approach represents the initial steps in improving the state of care by reducing risk and mortality, improving postoperative recovery, and potentially reducing operating room times.

In our previous work, we tracked a foreign body in a beating heart phantom to study its behavior<sup>7</sup>. We then found that speed of the foreign body is too fast for a robot to directly pursue it<sup>8</sup>. To provide a relatively slow robot with the ability to retrieve an erratically moving target, we proposed the concept of guiding a robot to a selected location and ambushing the target upon its reappearance to that location. We examined alternate indirect capture strategies<sup>7,9</sup> that relax the level of performance required of a robot. Leading into real-time capture experiments we studied the time evolution of computed capture locations<sup>10</sup>.

In this paper, we demonstrate the use of a high dexterity, minimally invasive surgical robot to retrieve a foreign body from a beating heart phantom. Streaming 3D TEE imaging is used to track the foreign body, compute a suitable capture location, and guide the robot to secure it. This effort differs from related works that focus on rigid tools or on manual guidance.

This work was funded in part by Philips Research North America and in part by Johns Hopkins University internal funds.




**Fig. 1** Minimally invasive robotic retrieval of foreign bodies from the heart under 3D transesophageal echocardiography (TEE) guidance.

## MATERIALS AND METHODS

The experimental setup (Fig. 2) consists of a Philips iE33 xMATRIX Echocardiography System and X7-2t 3D TEE probe, a beating heart phantom, and a high dexterity robot. The robot consists of a seven-degree of freedom (DOF) IBM/JHU Lars robot holding a JHU snake robot, a 39.5-mm long, 4.2-mm diameter dexterous end effector with four distal DOF. The robot is inserted into the left ventricle of the heart via the apex. Fig. 3 shows this arrangement in detail.

A 3.2-mm steel ball representing a foreign body such as shrapnel is placed in the phantom, and the scene is imaged using the ultrasound probe at a rate of 20 volumes per second. Tracking of the foreign body is performed using a modified normalized cross-correlation method; previous reports<sup>7</sup> describe this process in greater detail.



**Fig. 2** Equipment setup for real-time capture experiments.



**Fig. 3** Detailed view of the experimental setup showing the position of the TEE probe, beating heart phantom, and snake robot inserted into the heart at a point near the apex.

## EXPERIMENTS

The attractivity of a small  $1.6 \times 3.2$  mm magnet was tested by advancing the magnet towards the foreign body and measuring the distance at which attraction occurred; this range was found to be  $4.2 \pm 0.8$  mm over 20 repetitions. The magnet is affixed to the tip of the snake robot to represent an abstract capture device with high attractivity within the capture range and negligible effect beyond it. A one-time preoperative registration is done to relate the coordinate systems of the ultrasound volumes and the robot.

Commencing each trial, the robot is teleoperated in coarse control mode to place the tip of the snake robot at the entry point of the beating heart phantom. This establishes the virtual remote center of motion (RCM), from which point the robot operates autonomously.

Then, the foreign body is interactively selected from still images to define a template to be tracked in the live image stream. Computation of capture locations based on spatial probability is then initiated. Once a suitable capture location is found, the tracker commands the robot to said location. When the end effector reaches its destination, visual inspection is used to determine whether the foreign body has been captured. The robot is then withdrawn from the beating heart phantom, and success or failure of the attempt is recorded.

## RESULTS AND DISCUSSION

An example foreign body capture sequence is shown in Fig. 4. The foreign body was extracted successfully in 14 out of 17 attempts (82.4%). In two of the three failed attempts, the foreign body shifted to a different location after a capture location was found; this phenomenon has been noted in our prior studies. The other failed attempt can be attributed to premature withdrawal of the robot before it completed its capture trajectory.

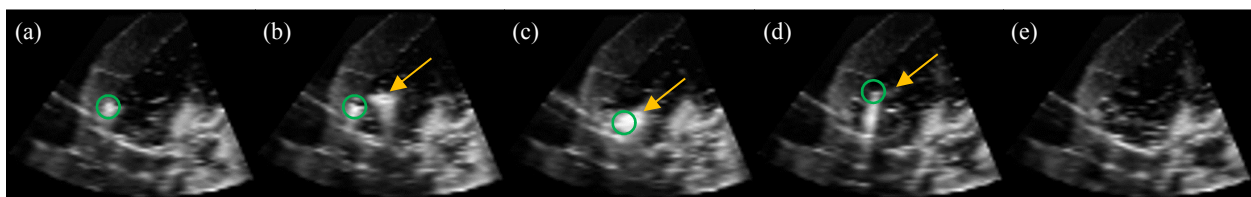
The mean observation time before executing a capture was  $29.6 \pm 6.9$  seconds, with extrema of 21.6

and 46.3 seconds. We reported an observation time for this method of roughly 20.0 seconds previously<sup>10</sup>, while noting large variations between trials. Such variability can be explained by the irregular motions traced by the foreign body. In light of these considerations, the values obtained in this study appear to be within reason.

The retrieval process was completed in  $97.7 \pm 21.6$  seconds. Though governed largely by human discretion, this figure serves as a reference in the context of cardiac procedures, which often last several hours. Potentially, the perioperative time incurred by robotic aspects would be minimal, and more sophisticated techniques can be used to improve outcomes. These results demonstrate the viability of using a slow, dexterous robot to capture an erratic cardiac target under 3D ultrasound guidance. Future work will include workflow optimization, sterility, tooling for capturing multiple types of targets, and possible integration of real-time X-ray imaging.

## REFERENCES

- [1] Marshall AJ, Ring NJ, Newman PL. An unexplained foreign body in the myocardium. *J. Royal Soc. Med.* 2002; 95: 250–251.
- [2] Symbas PN, Picone AL, Hatcher CR, Vlais-Hale SE. Cardiac missiles. A review of the literature and personal experience. *Ann. Surg.* 1990; 211(5): 639–48.
- [3] United States Department of Defense. *Emergency War Surgery: Third US Rev, s.l., 16: Thoracic Injuries* 2004.
- [4] Actis Dato GM, Arslanian A, Marzio PD, Filosso PL, Ruffini E. Posttraumatic and iatrogenic foreign bodies in the heart: report of 14 cases and review of the literature. *J. Thorac. Cardiovasc. Surg.* 2003; 126(2): 408–414.
- [5] Evans J, Gray LA, Rayner A, Fulton RL. Principles for the management of penetrating cardiac wounds. *Ann. Surg.* 1979; 189(6): 777–784.
- [6] Nessen SC, Lounsbury DE. *War Surgery in Afghanistan and Iraq: A Series of Cases, 2003-2007, s.l. Department of the Army, Office of the Surgeon General and Borden Institute, 14: Thoracic Trauma* 2008.
- [7] Thienphrapa P, Elhawary H, Ramachandran B, Stanton D, Popovic A. Tracking and characterization of fragments in a beating heart using 3D ultrasound for interventional guidance. *MICCAI* 2011; 6891: 211–218.
- [8] Thienphrapa P, *et al.* A system for 3D ultrasound-guided robotic retrieval of foreign bodies from a beating heart. *IEEE/EMBS BioRob* 2012; 743–748.
- [9] Thienphrapa P, Ramachandran B, Elhawary H, Taylor RH, Popovic A. Multiple capture locations for 3D ultrasound-guided robotic retrieval of moving bodies from a beating heart. *SPIE Medical Imaging* 2012; 8316.
- [10] Thienphrapa P, *et al.* Intraoperative analysis of locations for 3D ultrasound-guided capture of foreign bodies from a beating heart. *Hamlyn Symp. Medical Robotics* 2012.



**Fig. 4** Image sequence showing different phases of foreign body capture. (a) Foreign body (circle) in the heart ventricle just before a capture location is determined. (b) Dexterous robot (arrow) approaches capture location. (c) Robot captures foreign body. (d) Robot leaving heart with foreign body attached. (e) Heart empty after foreign body is extracted.